

Change of Bifurcation Stenting Strategy In Case Of Non-Q Wave Myocardial Infarction: From V-Stenting to Mini Crush Technique -A Case Report

¹Rohit Mody, ²Debabrata Dash, ³Bhavya Mody, ⁴Aditya Saholi, ⁴Shubham Sachdeva

¹Department of Cardiology, MAX Super specialty hospital, Bathinda, Punjab, India

²Department of Cardiology, Zulekha Hospital, Sharjah, UAE

³Department of Medicine, Kasturba medical college, Manipal, Karnataka, India

⁴Department of Medicine, Irwin Hospital, Malout, Punjab, India

*Correspondence to: Rohit Mody, Department of Cardiology, MAX Super specialty hospital, Bathinda, Punjab, India, E-mail: drmody2k@yahoo.com

Received: 01 December 2020; Accepted: 18 December 2020; Published: 30 December 2020

Copyright: © 2020 Mody R. This is an open-access article distributed under the terms of the Creative Commons Attribution License, which permits unrestricted use, distribution, and reproduction in any medium, provided the original author and source are credited.

Abstract

Percutaneous treatment of coronary bifurcation is a typical area where controversy regarding stenting techniques is still there. While provisional stenting (PS) of the side branch is a practical and effective technique, there are number of cases where two stent techniques are needed. We present here a case of a 69-year-old gentleman presenting with Acute coronary syndrome (ACS) with ongoing chest pain was subsequently diagnosed to have right coronary artery (RCA) bifurcation lesion (Medina 0,1,1) where a change of stenting strategy from V-stenting to mini crush enabled us to tide over the complications.

A 69-year-old gentleman, non-diabetic, nonsmoker normal body mass index (BMI), with a past history of coronary artery disease (CAD), with ACS was transferred to our catheterization lab in view of recurrent chest pain and dynamic ST-T changes. Electrocardiogram (ECG) showed ST-T changes in inferior leads and Echocardiography (ECHO) showed regional wall motion abnormalities (RWMA) in RCA territory. A diagnosis of CAD, non-Q myocardial infarction (MI) was made. Coronary angiography (CAG) revealed triple vessel disease with culprit vessel was identified as distal RCA with bifurcation into posterior descending artery (PDA) and posterolateral vessel (PLV) with thrombolysis in myocardial infarction (TIMI) grade - 3 clot. Two stent strategies with V-stenting were contemplated due to ongoing chest pain and dynamic ST-T changes. Two Drug-eluting stents (DES) from distal RCA to PLV and PDA in a V fashion were implanted simultaneously. However, it resulted in edge dissection at the proximal edge of overlapping stents. Hence, another long stent 3 x 33mm DES was deployed from PLV to distal RCA crushing the PDA stent which was then recrossed and sequentially balloon dilated and final kissing balloon dilatation was performed with the excellent final result.

V-stenting can be an attractive two-stent strategy in patients of bifurcation where clinically there is an acute situation and PCI must be completed in the shortest possible time with minimal complicity. In case of complication of proximal edge dissection in V-stenting technique, the strategy can be changed to mini crush to bail out the complications.

Keywords: PCI, Bifurcation stenting, unstable angina, V stenting, Mini crush, Myocardial Infarction

Introduction

PCI of bifurcation lesions is complex and challenging [1]. Regardless of the technique, restenosis rates after bare-metal stenting (BMS) were high (40% to 60%), especially at the ostium of the side branch (SB) [1-3] where lesions frequently present with negative remodelling after PCI and suboptimal angiographic results before PCI [4]. With the advance of DES, the “crush” technique has been proposed to treat bifurcation lesions because of its predictability, high procedure success rate, and full coverage of the SB ostium [5-6].

The V-stenting technique was reported first in 1993 by Colombo et al. Since the introduction of the V-stenting technique, the major concerns are two-barrel metallic carina which may act as a stimulus

for stent thrombosis. Optical coherence tomography (OCT) study in two patients who underwent treatment for bifurcation lesion by V-stenting technique reported that the struts in the metal carina were completely covered with the tissues and no uncovered or incomplete struts apposition was observed. The authors in another study reported that after 4-months of implantation with the V-stenting technique, the metallic carina was completely endothelialized [7].

Case presentation Patient history and presentation

A 69-year-old gentleman non-diabetic, non-smoker, known case of hypertension with a family history of CAD, and normal body weight presented to the emergency department with complaints

of breathlessness and chest pain at rest. He was transferred to our catheterization lab in view of recurrent chest pain and dynamic ST-T changes. The patient had hemodynamic instability with the blood pressure of 100/70 on inotropic support.

Differential diagnoses

In this patient, the ACS was most suspected, followed by myocarditis, pericarditis, and stress cardiomyopathy.

Investigations

His ECG showed ST depression in inferior leads and ECHO showed RWMA in RCA territory with ejection fraction (EF) of 40%. He had non-ST elevation MI. He was immediately taken for a CAG. His angiogram revealed triple vessel disease (Figure 1). RCA was the culprit vessel which revealed a lesion of distal RCA 85% and its bifurcation into PLV and PDA at the origin of 95% with TIMI grade-3 clot. The patient's proximal left anterior descending (LAD) was normal but mid LAD showed 85% discrete lesion and left circumflex (LCX) showed diffuse distal disease. The patient's Syntax score was calculated and was found to be 26. Heart team considerations were taken. Patient opted for staged PCI with stenting of RCA, PLV, PDA as a first stage procedure.

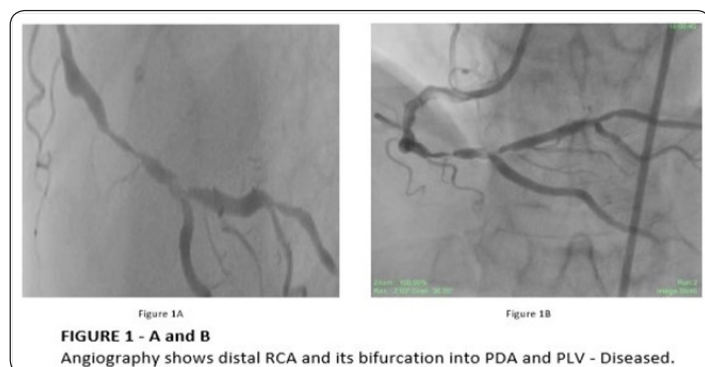


Figure 1A and 1B: Angiography shows distal RCA and its bifurcation into PDA and PLV- Diseased

Management

The RCA was engaged with a JR4 catheter (Medtronic). The lesions were crossed with two BMW wires (Abbott Vascular, Santa Clara, California, United States) (Figure 2 - A, B), two DES (Tetralimus-eluting, Sajanand Medical technologies, Surat, India) 3 x 18 mm in PLV and 2.75 x 18 mm in PDA with markers of the stent in distal RCA (Figure 2C). The two stents were deployed at 18 atm each simultaneously (Figure 3A). Direct stenting was done in view of the presence of a clot. Direct stenting, in our experience, gives better outcomes like less no-reflow phenomenon. A dissection was observed proximal to stents in distal RCA (Figure 3B). A bail-out stenting was done with 3 x 33 mm DES (Tetralimus-eluting, Sajanand Medical technologies, Surat, India) deployed from PLV to distal RCA at 18 atm crushing the stent (Figure 3: C, D, E). The crushed stent was recrossed with BMW wire (Figure 4A), then a passage was made by dilatation with a 1.5 x 10 mm non-compliant (NC) balloon (Mozec NC; Meril) through the crushed stent (Figure 4B). The crush stent was further dilated through struts with a 3 x 15 mm NC balloon (Mozec NC; Meril) at 18 atm (Figure 4C). The procedure was completed by kissing balloon dilatation with 3.5 x 15 mm NC balloon (Mozec NC; Meril) in PLV and 3 x 15 mm in PDA (Traveler balloons; Boston Scientific, Marlborough, Massachusetts, USA) at 12 atm (Figure 4D). Finally, a post-dilatation to

the third stent was done with a 3.5 x 15 mm NC balloon (Mozec NC; Meril). There was a good final result (Figure 4E).

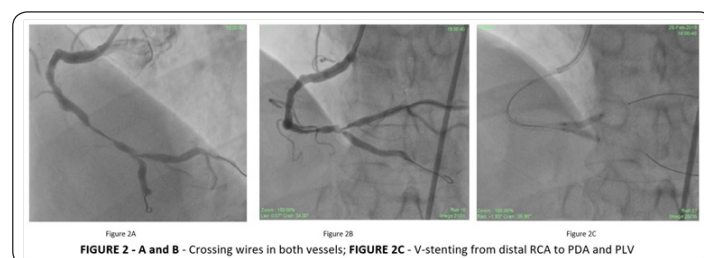


Figure 2A and 2B: Crossing wires in both vessels

Figure 2C: V stenting from distal RCA to PDA and PLV

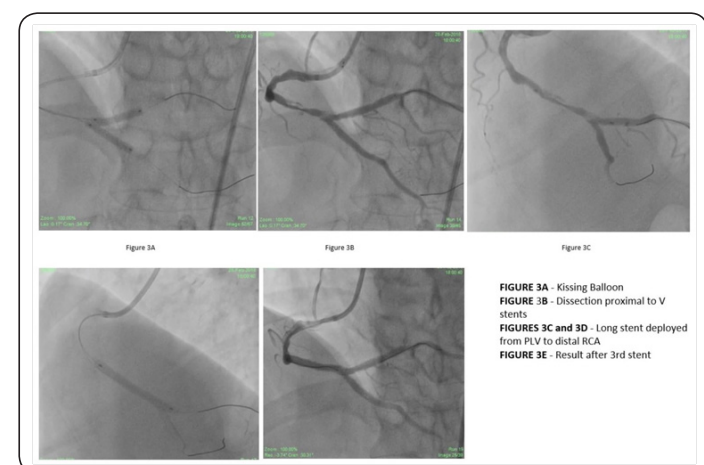

Figure 3A: Kissing Balloon

Figure 3B: Dissection proximal to V stents

Figures 3C and 3D: Long stent deployed from PLV to distal RCA

Figure 3E: Result after 3rd stent

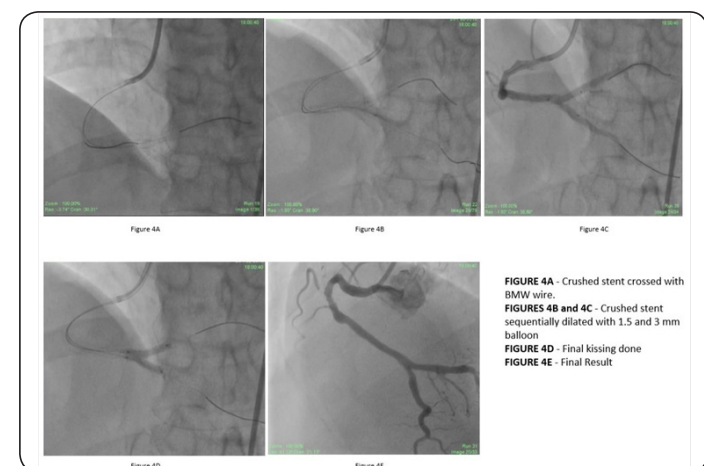

Figure 4A: Crushed stent crossed with BMW wire

Figures 4B and 4C: Crushed stent sequentially dilated with 1.5- and 3-mm balloon

Figure 4D: Final kissing done

Figure 4E: Final Result

Outcome

The final result was good with TIMI-3 flow and the complication of edge dissection was taken care of by putting another stent and converting the procedure into crush technique. The patient was discharged after 2 days of observation.

Follow up

The patient was followed up after 15 days in the outpatient department. The PCI to LAD was performed as a second-stage procedure. The patient was then followed up 3-monthly, up to one year. The patient was free of angina, with no symptoms pertaining to the cardiovascular system. His ECG was unremarkable and ECHO showed EF of 50%.

Discussion

V-stenting is a two-stent technique entailing the delivery and implantation of two stents simultaneously keeping two-barrel metallic carina in the main vessel. The main advantages of V-stenting are that it assumes vessel patency in both branches; the final kissing balloon dilatation is done simultaneously without the need for rewiring. This technique becomes especially important in emergencies in unstable patients where accidental occlusion of the SB is expected to be very poorly tolerated [7]. A major concern with the V-stenting technique is that it is difficult to place a stent proximally if a complication occurs. In our case, a dissection was observed proximal to the metallic carina. Hence, the best way to bail this out was placing a long DES from the PLV branch to distal RCA also covering the lesions of distal RCA and converting it into a mini crush procedure. The mini crush technique may not completely resolve the potential problem of bifurcation stenting that is the stent apposition of the SB [8]. Intravascular ultrasound (IVUS) analysis showed that although final kissing inflation was performed in 90% of the patients, incomplete apposition of the SB or main vessel was found in 60% of non-left main lesions [9]. In prior multicenter randomized trials, double kissing (DK) crush planned two stent technique resulted in lower rates of target vessel revascularization (TLR) compared with provisional stenting (PS) in non-left main coronary bifurcation lesions [10]. The crushing technique needs a kiss appropriately conducted. We should have known this from the beginning “if you get a crush you should then kiss and if you kiss you should do it well” [11]. In our case, we proceeded with two-stent strategy as the patient had non-Q wave MI and was unstable hemodynamically and both side branches were significant in size. We preferred V-stenting over other rival stenting techniques because with ongoing chest pain and hemodynamic instability, an accidental occlusion of the branch would have been poorly tolerated and we would be able to convert it into a mini crush technique successfully. We executed the kissing technique during crush procedure with dilatation of the SB with an NC balloon before kissing to give appropriate results. We planned to cover the distal RCA lesion with a third stent deployed proximally. But, as we saw the edge dissection abutting the proximal edge of stented V, we decided to bail this complication with converting the procedure to mini crush for better results. Moreover, deploying simply a third stent proximally would have been a nidus for future complications of stent failure.

Conclusion

V-stenting can be adopted in emergencies as a two-stent strategy because it assures vessel patency in both branches. But in case of complications like edge dissection, as it occurred in our patient, we can change our bifurcation stenting strategy and can convert this technique to mini crush technique to bail out the complication.

Summary points

- Direct stenting using V technique can be adopted in patients where more complicated techniques might result in difficulty in handling these patients in the catheterization lab on table. We can get good

results even with older techniques like V-stenting which are simpler to execute.

- In case of complications like edge dissection we can bail the complication by putting a third stent proximally but the better way is to convert the procedure into mini crush technique.

Abbreviations

PCI-	Percutaneous Intervention
SB	- Side branch
OCT-	Optical coherence tomography
CAD-	Coronary artery disease
ECG-	Electrocardiogram
EF-	Ejection Fraction
PLV-	Posterolateral vessel
PDA	- Posterior descending artery
TIMI score	- Thrombolysis in Myocardial Infarction Score
DES-	Drug eluting stent
CAG	- Coronary Angiography
ECHO	- Echography
IVUS-	Intravascular Ultrasound
TLR-	Target-vessel revascularization
DK-	Double kissing
PS-	Provisional stenting
NC	- Non-compressible
CPK-MB-	Creatine Phosphokinase-MB
LAD	- left anterior descending
LCX-	Left Circumflex

References

1. Reimers B, Colombo A, Tobis J. Bifurcation lesions. “Colombo A, Tobis A Ed, Techniques in coronary artery stenting, Martin Dunitz Ltd, London (2000): 171-204.
2. Yamashita T, Nishida T, Adamian MG, Briguori C, Vagheti M, Corvaja N et al. “Bifurcation lesions: two stents versus one stent—immediate and follow-up results”. *J Am CollCardiol* 35(2000): 1145-1151.
3. Gobeil F, Lefevre T, Guyon P, Louvard Y, Chevalier B, et al. “Stenting of bifurcation lesions using the bestent: a prospective dual-center study”. *Catheter CardiovascInterv* 55(2002): 427-433.
4. Kobayashi Y, Mehran R, Moussa I, Reyes A, Moses JW. “Negative remodeling at the ostium of the left circumflex artery”. *J Invasive Cardiol* 13(2001): 805-807.
5. Colombo A, Stankovic G, Orlic D, Corvaja N, Liistro F, et al. “Modified T-stenting technique with crushing for bifurcation lesions: immediate results and 30-day outcome”. *Catheter CardiovascInterv* 60(2003): 145-151.
6. Daemen J, Lemos PA, Serruys PW. “Multi-lesion culotte and crush bifurcation stenting with sirolimus-eluting stents: long-term angiographic outcome”. *J Invasive Cardiol* 15(2003): 653-656.

7. Kunwar BK, Pawar V, Villkhoo RS, Mishra S. "A high risk unstable case of left main bifurcation lesion treated with simultaneous kissing stents as salvage procedure". *Int J Res Med Sci.* 8(2020): 764-766.
8. Ormiston JA, Currie E, Webster MW, Kay P, Ruygrok PN, et al. "Drug-eluting stents for coronary bifurcations: Insights into the crushing technique". *Catheter CardiovascInterv* 63(2004): 332-336.
9. Costa RA, Mintz GS, Carlier SG, Lansky AJ, et al. "Bifurcation coronary lesions treated with the "crush" technique: An intravascular ultrasound analysis". *J Am CollCardiol* 46(2005): 599-605.
10. Chen SL, Zhang JJ, Han Y, Kan J, Chen L, et al. "Double kissing crush versus provisional stenting for left main distal bifurcation lesions DK crush- a randomized trial". *J Am CollCardiol* 70(2017): :2605-2617.
11. Colombo A. "Bifurcational lesions and the "crush" technique: understanding why it works and why it doesn't-a kiss is not just a kiss". *Catheter CardiovascInterv* 63(2004) 337-338.

Citation: Mody R. "Change of Bifurcation Stenting Strategy In Case Of Non-Q Wave Myocardial Infarction: From V-Stenting to Mini Crush Technique-A Case Report". Doi: 10.47755/J Heart Cardiovac Sci.2020.1.005